

# Active *Leptospermum* Honey Impregnated Calcium Alginate Dressing\* Facilitates Healing in Elderly Patients with Painful Chronic Wounds Unable to Tolerate Silver Containing Dressings

Loren C. Hayes, ARNP, GNP-BC, MS(N), GCNS-BC, MS, CWCN, CWS, FACCWS, DAPWCA  
Wound Technology Network, Hollywood, FL.; lhayes@woundtech.net

## INTRODUCTION

Chronic wounds, "stuck" in the inflammatory stage of healing, are often treated with silver containing dressings. Some patients treated with silver experience intolerable burning and stinging. Over the past decade researchers have found a honey with plant derived characteristics that make it ideal for use in wound care. Active *Leptospermum* Honey Impregnated Calcium Alginate Dressing (HICAD)\* used as a wound dressing has demonstrated both antimicrobial properties promoting rapid healing and an anti-inflammatory action secondary to the presence of antioxidants. These antioxidants absorb free radicals produced during the process of inflammation, which in turn reduces pain and swelling.

## OBJECTIVE

Investigate the efficacy and tolerance of an Active *Leptospermum* HICAD in elderly patients with painful, chronic wounds who are intolerant of silver dressings.

## METHODS

A case series of six patients (60-78years old) with painful, chronic wounds of varying etiology were enrolled in the study. Previous treatment with silver based dressings caused burning and intolerance. Twice weekly conservative sharp debridement was followed by application of the Active *Leptospermum* HICAD covered with non-active secondary dressings over a 12 week period. Evaluation included documentation of wound size, level of pain, signs and symptoms of inflammation and photographs to monitor and assess overall efficacy, healing and tolerance.

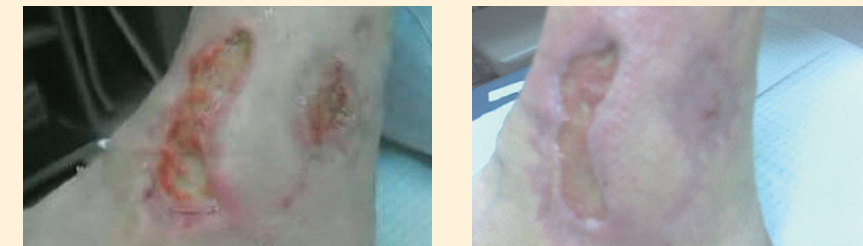## RESULTS

All six patients demonstrated a marked decrease in clinical signs and symptoms of inflammation, improvement in pain level and tolerated treatment with the HICADs. None of the patients reported burning. Evidence of healing was demonstrated by each patients' wound having minimum of 81% decrease (average 96% decrease) in overall area and a minimum of 87% decrease (average 97% decrease) in overall volume calculated electronically.

## CONCLUSION

In this limited case series, the use of Active *Leptospermum* HICAD was associated with positive wound healing outcomes, decreased inflammation and pain in elderly patients with chronic wounds unable to tolerate silver containing dressings. A larger sample size and further research is suggested to confirm these findings.

### PATIENT 1



11/26/07

2/5/08

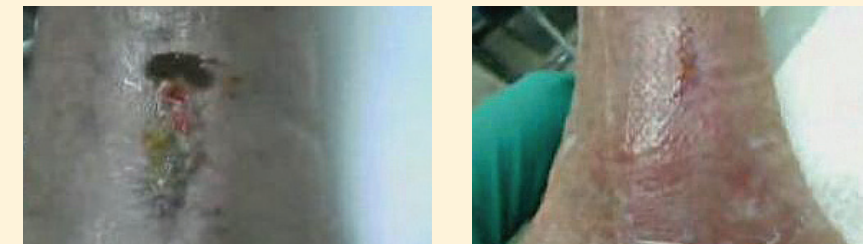
Vasulopathic wound present 8 months prior to starting Active *Leptospermum* HICAD

Prior Treatment - Cadaver graft, wound emulsion gel and silver products without success

11/26/07 - Start Date Active *Leptospermum* HICAD applied  
Area 21.16 Volume 6.35

2/5/08 - End Date Area 3.96 (81% improved)  
Volume 0.79% (87% improved)

### PATIENT 4



1/4/08

3/11/08

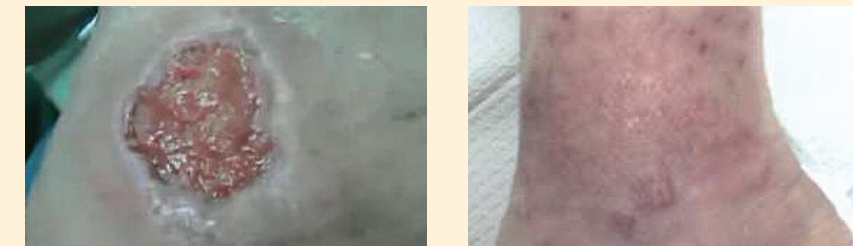Venous wound present 15 months prior to starting Active *Leptospermum* HICAD

Prior Treatment - Cellulose dressing, collagen, hydrocolloid, plain hydrogel and silver products without success

1/4/08 - Start Date Active *Leptospermum* HICAD applied  
Area 6.74 Volume 2.02

3/11/08 - End Date Area 0.05 (99% improved)  
Volume 0.0 (100% improved)

### PATIENT 2



12/7/07

3/11/08

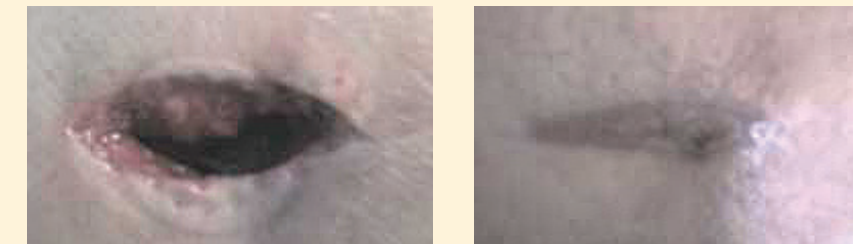
Venous wound present 4 months prior to starting Active *Leptospermum* HICAD

Prior Treatment - Hydrocolloid, Ca alginate, plain hydrogel and silver products without success

12/7/07 - Start Date Active *Leptospermum* HICAD applied  
Area 3.92 Volume 1.18

3/11/08 - End Date Area 0.13 (97% improved)  
Volume 0.01 (99% improved)

### PATIENT 5



1/26/08

3/15/08

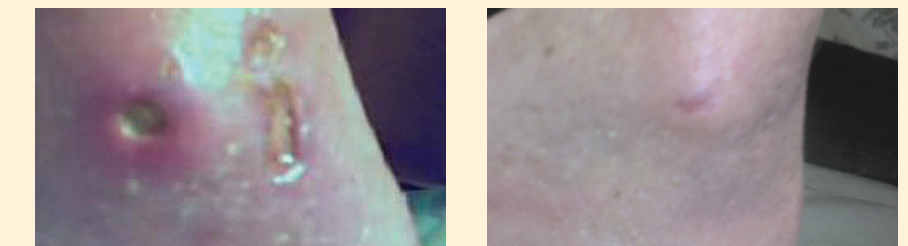
Traumatic wound present 2 weeks prior to starting Active *Leptospermum* HICAD

Prior Treatment - ORC matrix and silver products without success

1/26/08 - Start Date Active *Leptospermum* HICAD applied  
Area 11.78 Volume 31.79

3/15/08 - End Date Area 0.0 (100% improved)  
Volume 0,0 (100% improved)

### PATIENT 3



12/10/07

3/10/08

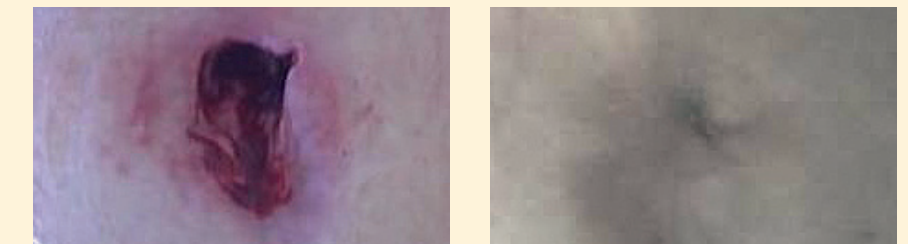
Vasculitic wound present 4 months prior to starting Active *Leptospermum* HICAD

Prior Treatment - Papain urea enzymatic, ORC matrix and silver products without success

12/10/07 - Start Date Active *Leptospermum* HICAD applied  
Area 3.63 Volume 0.36

3/10/08 - End Date Area 0.09 (98% improved)  
Volume 0.01 (97% improved)

### PATIENT 6



1/5/08

3/24/08

Surgical wound present 8 months prior to starting Active *Leptospermum* HICAD

Prior Treatment - Collagen and silver products without success

1/5/08 - Start Date Active *Leptospermum* HICAD applied  
Area 12.95 Volume 32.38

3/24/08 - End Date Area 0.0 (100% improved)  
Volume 0.0 (100% improved)

#### References:

Alcaraz, A., & Kelly, J. (2002). Treatment of an infected venous leg ulcer with honey dressings. *British Journal of Nursing*, 11(13), 859-866.  
Cutting, K.F. (2007). Honey and contemporary wound care: An overview. *Ostomy/Wound Management*, 53(11), 49-54.  
George, N.M. & Cutting, K.F. (2007). Antibacterial honey (Medihoney™): in-vitro activity against clinical isolates of MRSA, VRE, and other multiresistant gram-negative organisms including *Pseudomonas aeruginosa* Wounds, 19(9), 231-236.  
Henriques, A., Jackson, S., Cooper, R., & Burton, N. (2006). Free radical production and quenching in honeys with wound healing potential. *Journal of Antimicrobial Chemotherapy*, 58, 773-777.  
Tonks, A., Dudley, E., Porter, N., Parton, J., Brazier, J., Smith, E., et al. (2007). A 5.8-kDa component of manuka honey stimulates immune cells via TLR4 [Electronic Version]. *Journal of Leukocyte Biology*, 82, from <http://www.jleukbio.org> <<http://www.jleukbio.org>>

\*MEDIHONEY™ Absorbent Calcium Alginate Dressing with Active *Leptospermum* Honey, Derma Sciences, Inc., Princeton, New Jersey. Funding for costs associated with this poster provided by Derma Sciences. The information in this poster concerns a use that has not been approved or cleared by the US Food and Drug Administration.