

# Chronic Lower Extremity Venous Ulceration — Use of a *Leptospermum* Honey Impregnated Alginate to Facilitate Wound Closure

Matthew Regulski, DPM, CWS, FAPWCA, WHS, Director, Wound Care Center of Ocean County, Ocean County Foot and Ankle Surgical Associates  
Toms River, New Jersey

## INTRODUCTION

Chronic lower extremity venous ulceration presents ongoing challenges for clinicians who manage exudates, pain and inflammation.

## OBJECTIVE

To evaluate wound healing using a *leptospermum* honey impregnated calcium alginate dressing and compression bandaging for the treatment of chronic lower extremity venous ulceration.

## METHODS

Eight patients with chronic venous ulceration were enrolled in a 12 week trial. All wounds had previously been non-responsive to treatment with compression along with either alginate or collagen dressings. *Leptospermum* honey impregnated calcium alginate dressings were applied once weekly along with compression bandaging.

## OUTCOME

Use of *leptospermum* honey impregnated calcium alginate dressings for chronic lower extremity wounds demonstrated accelerated healing, diminished pain, inflammation, exudates and maceration. Wound healing was accelerated in all cases with 100% closure for 5 patients at 6 weeks. The remaining 3 patients achieved 75% closure at the end of the study period (12 weeks). The overall healing rate was 91.375% for all 8 wounds.

Diabetic patients (n=5) performed routine glucose monitoring throughout the trial and no change in their usual glucose level was noted with the use of the honey dressing at any time.

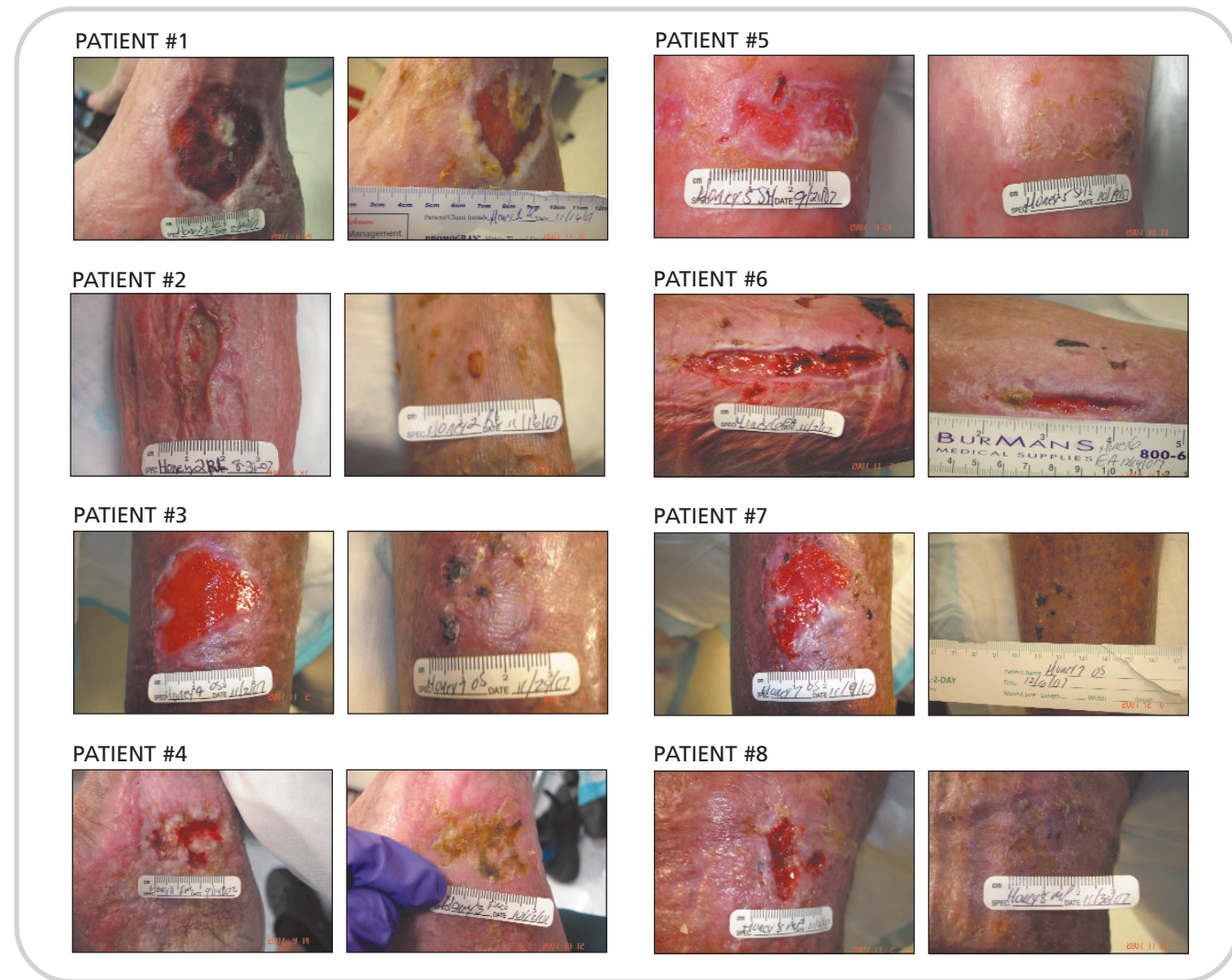
## CONCLUSION

*Leptospermum* honey impregnated calcium alginate dressings facilitated wound closure, decreased pain and inflammation, assisted with management of exudates and periwound edema and did not produce a rise in blood sugar in the diabetic patient, in this series of patients with chronic lower extremity venous ulceration.

PATIENT	DATE	MEASUREMENTS
PATIENT #1	8-24-07 11-16-07	Length 3.91 x Width 5.01, Area 14.163 Length 1.98 x Width 3.85, Area 4.053
PATIENT # 2	8-31-07 11-16-07	Length 1.16 x Width 3.02, Area 2.551 Healed
PATIENT # 3	11-2-07 11-30-07	Length 2.94 x Width 2.12, Area 4.826 Healed
PATIENT # 4	9-14-07 10-12-07	Length 4.15 x Width 3.13, Area 8.74 Length 0.94 x Width 0.65, Area 0.568
PATIENT # 5	9-21-07 10-19-07	Length 3.88 x Width 1.89, Area 5.354 Healed
PATIENT # 6	11-2-07 12-11-07	Length 1.01 x Width 5.46, Area 4.149 Length .51 x Width 4.54, Area 1.582
PATIENT # 7	11-9-07 12-6-07	Length 3.25 x Width 3.08, Area 8.083 Healed
PATIENT # 8	11-2-07 11-30-07	Length 1.02 x Width 3.44, Area 2.927 Healed

### References:

- Cooper, R., & Gray, D. (2005). The control of wound malodour with honey-based wound dressings and ointments. [Electronic Version]. *Wounds UK*, Supplement 1, 26-31. Retrieved July 12 2007 from [http://www.woundsuk.com/downloads/honey\\_supplement.pdf](http://www.woundsuk.com/downloads/honey_supplement.pdf).
- George, N. M., & Cutting, K. F. (2007). Antibacterial honey (Medihoney™): in-vitro activity against clinical isolates of MRSA, VRE, and other multiresistant gram-negative organisms including *Pseudomonas aeruginosa*. *Wounds*, 19(9), 231-236.
- Gethin, G., & Cowman, S. (2005). Case series of use of Manuka honey in leg ulcerations. *International Wound Journal*, 2(1), 10-15.
- Tonks, A. J., Dudley, E., Porter, N. G., Parton, J., Brazier, J., Smith, E. L., et al. (2007). A 5.8-kDa component of manuka honey stimulates immune cells via TLR4 [Electronic Version]. *Journal of Leukocyte Biology*, 82 from <http://www.jleukbio.org>.



\*MEDIHONEY™ Absorbent Calcium Alginate Dressing with *Leptospermum* Honey, Derma Sciences, Inc., Princeton, New Jersey. Funding for costs associated with this poster provided by Derma Sciences.